

# Clinical Applications of the Modified Crown Lengthening Procedure

*Dr. Eugene Kryshchalskyj, DDS, Dip. Perio, MSc (Perio), FRCDC; Mr. Eugene Kryshchalskyj, BHS; Mr. Alex Kryshchalskyj*

## INTRODUCTION

The crown lengthening (CL) procedure has many applications in the periodontal sphere. It can take the form of a gingivectomy, full or partial thickness flap approach with or without osteoplasty, or even a flapless technique.<sup>1</sup>

These techniques allow for the manipulation of the tissues of the periodontium (soft and hard) to satisfy either aesthetic or restorative purposes. CL increases exposure of the tooth structure to solve difficulties with excessive gingival display (in the case of gingival hyperplasia, for example) exposes subgingival tooth margins to enable proper restoration of the dental apparatus in situations of subgingival tooth decay or tooth fracture.<sup>2</sup>

It is very important to have an adequate width of keratinized gingiva around the tooth (at least 2 mm) to preserve gingival health.<sup>3</sup> After performing the CL procedure, principles of the biologic width (BW) as described by Garguilo,<sup>4</sup> must also be respected (Fig. 1 & cases 3-13). The term

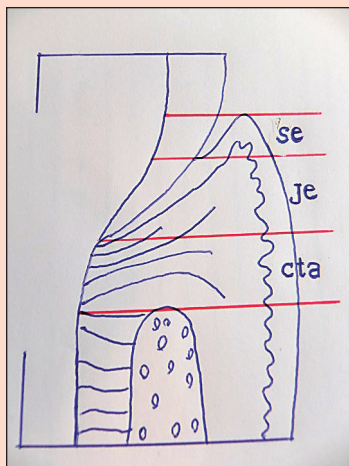
biologic width was originally coined by Walter D. Cohen in 1962. The mean dimensions of the BW were determined as follows: 1.07 mm for connective tissue, 0.97 mm for the epithelial attachment and 0.69 mm for sulcus depth were described as the BW for a total of 2.73 mm.<sup>4</sup> In clinical terms, this is averaged to 1 mm connective tissue attachment, 1 mm of junctional epithelium and 1 mm sulcus depth. As described, the BW is found in 85% of teeth while 2% would be under the total of 3 mm and 13% would exceed it.<sup>5</sup> Violation of that space by restorations invading the BW can and often lead to gingival inflammation, discomfort, gingival recession, alveolar bone loss and pocket formation<sup>6</sup> (Fig. 2).

It is desirable to expose at least 1 mm of subgingival tooth structure to satisfy retention and resistance form for the future restoration and facilitate appropriate visibility for the restorative dentist (Fig. 3). This permits incorporation of the ferrule effect, imparted by a band of tooth structure circumscribing the external

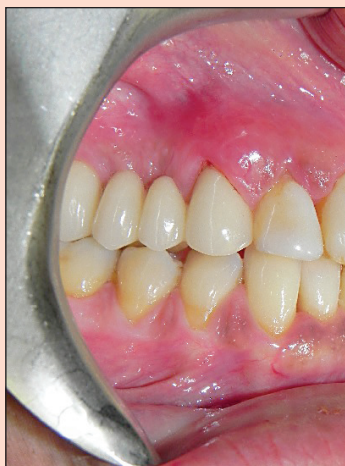dimension of the prepared teeth. The ferrule reinforces the tooth and its external surface and reduces the incidence of fracture especially in non-vital teeth.<sup>7</sup> The BW principle therefore gives preemptive insight towards surgical treatment planning when the above factors are considered.

## HEALING STUDIES

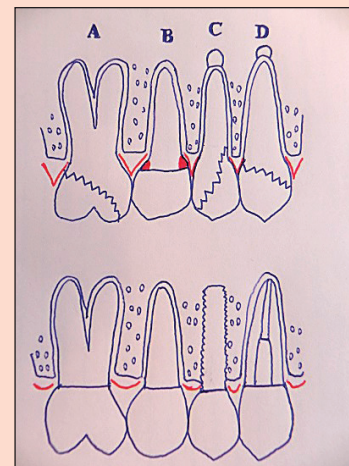
It is important to allow for healing in a protected periodontal environment to enhance patient comfort and full recovery of the periodontal tissues before initiation of the prosthetic phase. Many articles suggest healing times of 6-12 weeks, or 3-6 months, prior to completing the final restoration.<sup>8</sup> Factors that affect the postoperative reconstitution of the BW include gingival biotype, immediate post-suturing position of the flap, inter-individual variation of the biologic width, amount of osseous resection, post-surgical bone remodelling and clinical experience of the operator.<sup>8</sup> Several authors suggest more than 6 months of healing for final soft tissue stabilization if CL involves significant osteoplasty. At times a secondary



**FIGURE 1**—Schematic representation of the Biologic Width concept. SE (sulcular epithelium, 0.69 mm), JE (junctional epithelium, 0.97 mm) and CTA (connective tissue attachment, 1.07 mm).



**FIGURE 2**—When the biologic width is violated, gingival inflammation, swelling, discomfort, alveolar bone loss, and pocket formation occur. This patient complained of these symptoms within days of bridge cementation (teeth 13-to-16).



**FIGURE 3**—Various tooth fracture scenarios (A,B,C,D of the first row) and the corresponding management in the second row.

- 3A.** Favourable molar fracture without endodontic involvement. Tooth 16 restored with full coverage crown following CL surgery.
- 3B.** Tooth decay under existing crown without endodontic involvement. Full coverage crown replaced following CL surgery.
- 3C.** Unfavourable infrabony tooth fracture with endodontic involvement. Tooth extraction and implant placement consideration.
- 3D.** Favourable crown fracture with endodontic involvement. Endodontic treatment, post-core placement followed by CL surgery and full coverage restoration.

The second row shows the basis of CL surgery. When a tooth is decayed or broken below the gum line, CL surgery might be needed to adjust the gum and bone level to expose more of the tooth to permit restorative endeavours.

surgery would be required to refine surgical margins.<sup>9</sup>

Waiting for a final restoration for an extended a period could discourage patients from accepting this form of treatment. Furthermore, the longer a non-vital tooth is unprotected the greater is the likelihood of a secondary fracture to occur during the healing period. One wonders if a modification of surgical technique could perhaps diminish this waiting period. To look into this it is useful to review additional healing studies.

Ong et al<sup>2</sup> summarized that four to six weeks of tissue maturation is needed if only gingivectomy/gingivoplasty was done. Conversely, if a buccal flap was

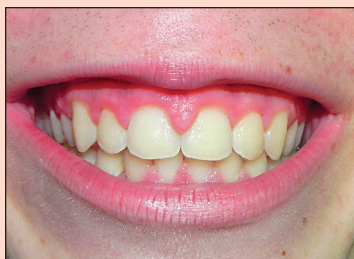raised and bone exposed, then eight to 12 weeks would be required for the tissue maturation and stabilization. If bone removal of significance was part of the CL (some articles suggest 2-3 mm of bone removal is necessary for this distinction), then six months of healing time is encouraged for many patients.<sup>2</sup> This timeframe might not be desirable as it may lead to increased tooth mobility, potential loss of interdental papilla (black triangle papilla deformity) and increased risk of post-operative surgical morbidity.

In a human study comparing mucoperiosteal flap procedure with and without osteoplasty, Donnenfeld et al<sup>10</sup> demonstrated that pocked reduction (which also occurs with CL procedures)

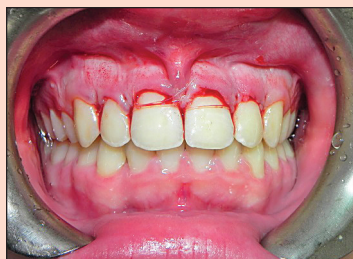
can be achieved with mucoperiosteal flaps in the absence of osteoplasty. Furthermore, the alveolar bone profile undergoes favourable remodelling changes following mucoperiosteal flap procedures in the absence of osteoplasty. Finally, “the combined effect of bone “grinding” and the resorptive process that follows contributes to greater bone loss than that which would occur following mucoperiosteal procedures alone”.<sup>10</sup>

In a rare human histological study with 23 patients, where 1 mm osteoplasty was performed, Wilderman et al<sup>11</sup> demonstrated that the average loss of alveolar bone was 0.8 mm over a period of three weeks to 18 months. Thin vestibular bone specimens lost a

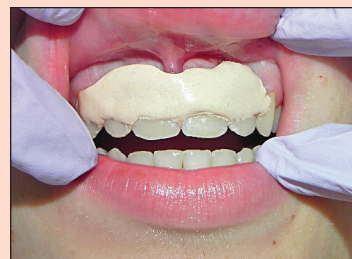**CASE 1.** 15-year-old male with gingival hyperplasia and excessive gingival display around 13-23 following orthodontic treatment (superimposed on gingival predisposition).



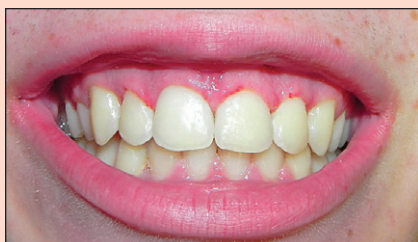**FIGURE 4A**—Pre-operative view.



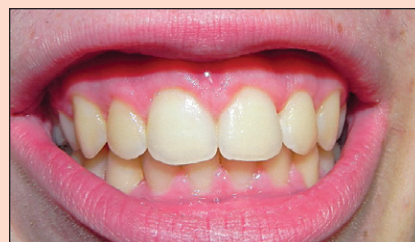**FIGURE 4B**—Conservative soft tissue CL provided without osteoplasty and secured with 5-0 gut sutures.



**FIGURE 4C**—Periodontal dressing placed.

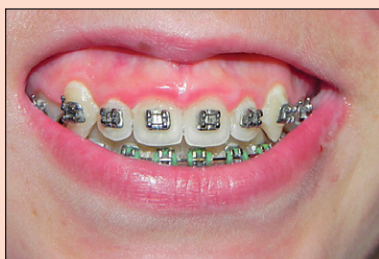

**FIGURE 4D**—One week favourable post-operative healing. Second periodontal dressing not required.

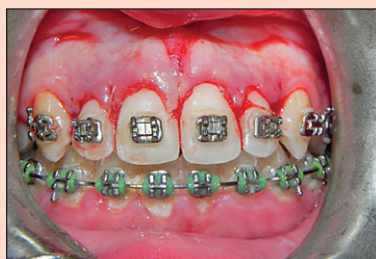

**FIGURE 4E**—One month post-operative healing showing complete stability and full smile.

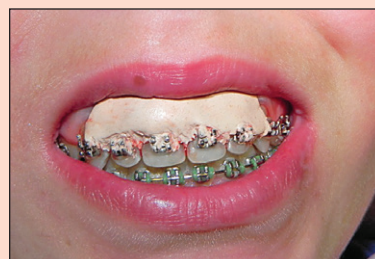**CASE 2.** 14-year-old male demonstrating excess gingival display (gingival hyperplasia) with negative aesthetic consequences.



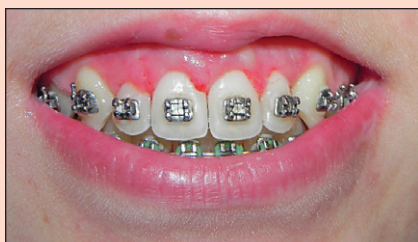**FIGURE 5A**—Preoperative view.



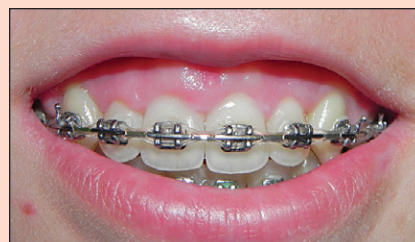**FIGURE 5B**—Soft tissue CL provided, secured with 5-0 gut sutures.



**FIGURE 5C**—Periodontal packing material placed.



**FIGURE 5D**—One-week post-operative healing. Second periodontal dressing not required.



**FIGURE 5E**—One-month healing and smile restored.

maximum of 3.1 mm and almost complete restoration of operated bone was achieved in a thick cancellous type bone with many marrow spaces.<sup>11</sup>

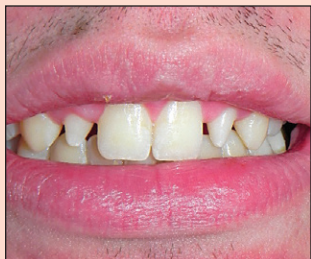With so many factors influencing periodontal healing, one wonders if some factors can be modified to favour a more conservative surgical technique in select circumstances to encour-

age a quicker healing sequence to facilitate earlier restorability of affected teeth.

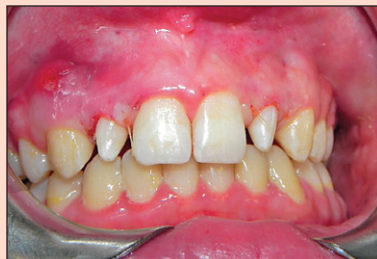In this regard, wound healing studies also show that 14



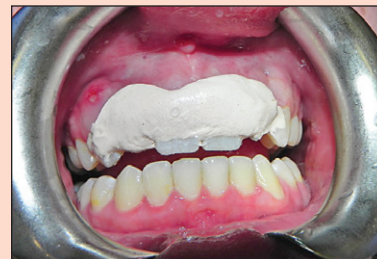**CASE 3.** 17-year-old male with gingival hyperplasia and incompletely formed crowns on “peg” laterals 12, 22.



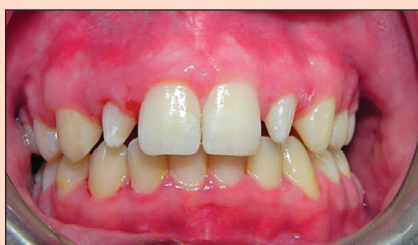**FIGURE 6A**—Pre-operative photo with compromised cosmetics.



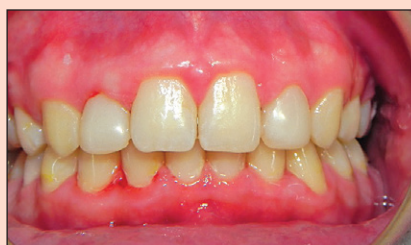**FIGURE 6B**—Post-operative view (soft tissues manipulation only) secured with 5-0 gut sutures.



**FIGURE 6C**—Periodontal dressing placed to protect and secure gingival position.

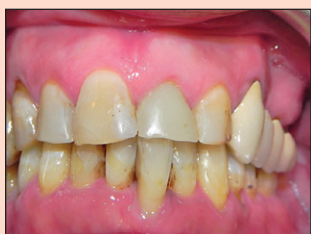

**FIGURE 6D**—First week p/o, favourable healing. Restoration to commence in the following week.

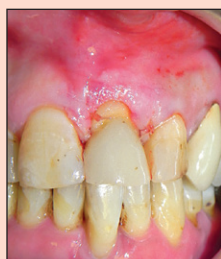

**FIGURE 6E**—Veneers placed on 12, 22 and function is restored, with significant cosmetic improvement (veneers completed by Drs. John and Joanna Kennedy). Oral hygiene was hindered by the presence of labial canker sores.

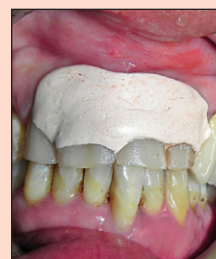**CASE 4.** 49-year-old male suffered labial crown fracture of endodontically-treated tooth 21.



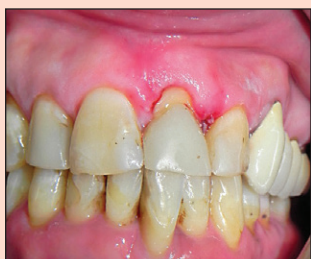**FIGURE 7A**—Pre-operative view showing labial fracture and gingival asymmetry with teeth 11 and 21.



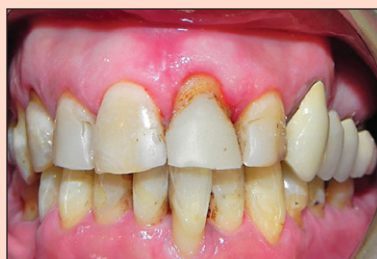**FIGURE 7B**—CL encompassed soft tissue manipulation more so than osteoplasty. Post-operative view prior to placement of first periodontal dressing.



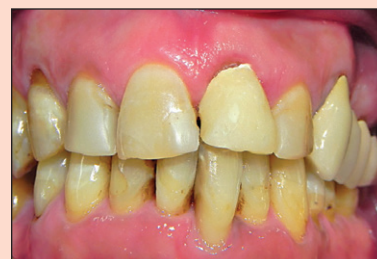**FIGURE 7C**—Periodontal dressing in position.



**FIGURE 7D**—One-week p/o healing demonstrates early epithelialization. Second periodontal dressing placed. The dressing also prevents “gingival rebound”.

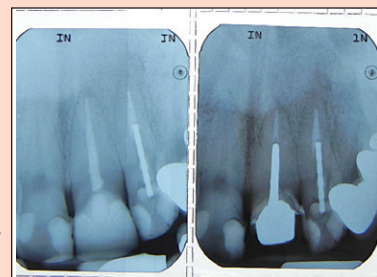


**FIGURE 7E**—Two-week post-op demonstrates more mature periodontal healing, but still immature. Third dressing is placed and general dentist will remove following week (“capture the margin”). Often times, an impression is able to be taken at this time.

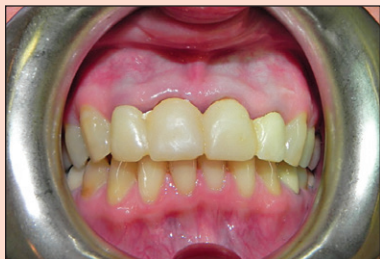

**FIGURE 7F**—Clinical photo of temporary crown and aesthetic harmony developing.

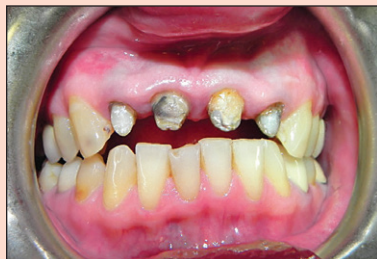**FIGURE 7G**—Pre and post-operative radiographs demonstrating osseous harmony.



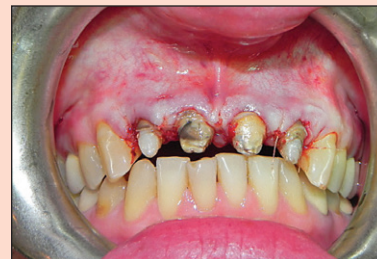**CASE 5.** 47-year-old male required four new crowns area 12-22 because of tooth decay and cosmetic reasons.



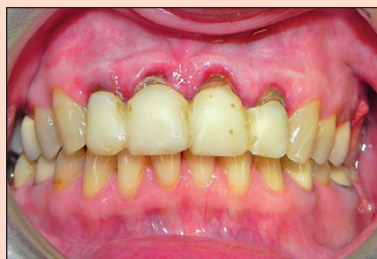**FIGURE 8A**—Temporary crowns placed initially to encompass extent of tooth decay. The temporary is removed during surgery to provide greater access interproximally to ensure close tissue adaptation for primary closure.



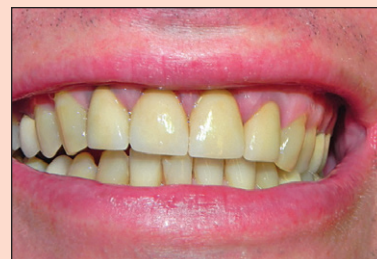**FIGURE 8B**—Pre-operative photo without temp splint.



**FIGURE 8C**—Surgical CL completed.

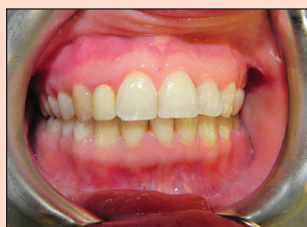

**FIGURE 8D**—Two-week post-op healing before a third dressing is placed. The general dentist will see the patient on third week of healing to refine margins and allow for further tissue maturation.

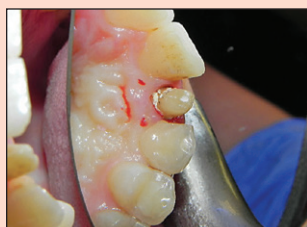

**FIGURE 8E**—Full coverage restorations completed four months after CL surgery (crowns completed by Dr. Iryna Sekunda).

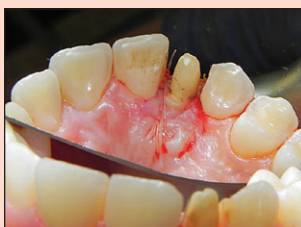**CASE 6.** 38-year-old female with recurrent decay area 12 palatal surface.



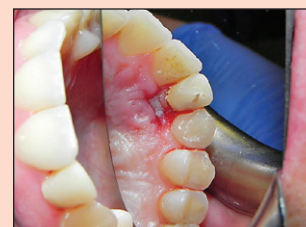**FIGURE 9A**—Pre-operative view labially.



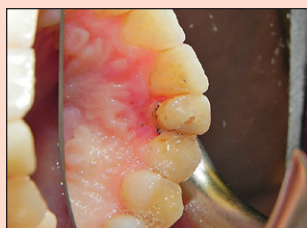**FIGURE 9B**—Pre-operative view palatally.



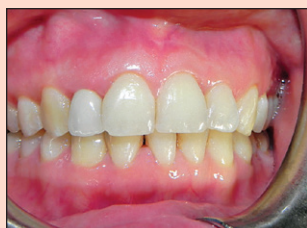**FIGURE 9C**—Surgical access primarily on palatal aspect to avoid loss of interdental papilla. If papillae are violated, cosmetic and phonetic complications can ensue.



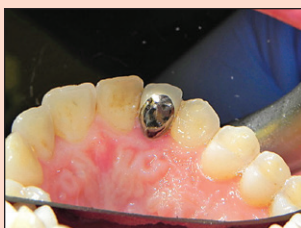**FIGURE 9D**—One-week post-op. Notice tissue is fragile and at this time second dressing is placed to prevent “gingival rebound” and allow for tissue maturation. Food trauma is also prevented in this way.



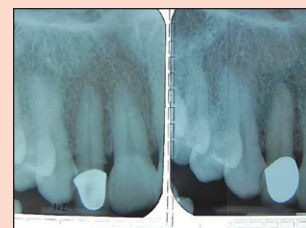
**FIGURE 9E**—After two-weeks of healing, tissues are more mature. General dentist will remove third dressing the following and “capture the margin”.



**FIGURE 9F**—Post-operative view labially. Notice papillae are maintained. At lab, patient over-compensated for colour choice and is pursuing “tooth bleaching” efforts.



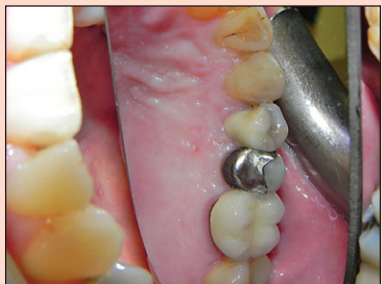**FIGURE 9G**—Palatal surface of 12 showing gingival harmony.



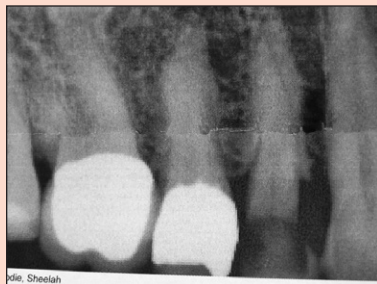**FIGURE 9H**—Pre and post-operative radiographs demonstrating excellent marginal fit of new full-coverage restoration (restoration provided by Dr. Musarrat Hasmain).



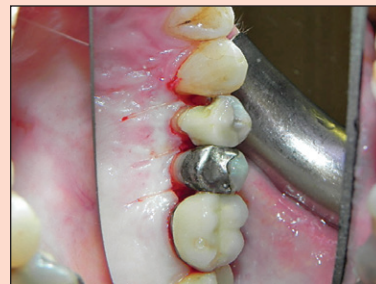**CASE 7.** 70-year-old female with palatal cusp fracture of tooth 14.



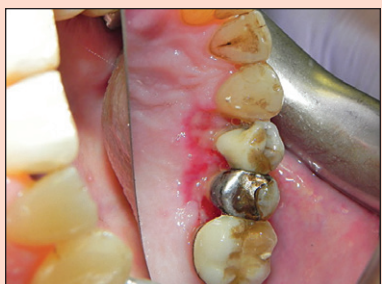**FIGURE 10A**—Pre-operative photo of tooth 14 revealing palatal fracture. Tooth is vital and does not require endodontic treatment.



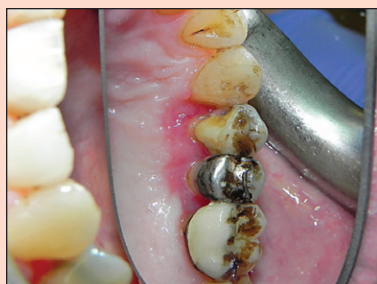**FIGURE 10B**—Periapical radiograph also showing some horizontal bone loss but tooth mobility factors are favourable.



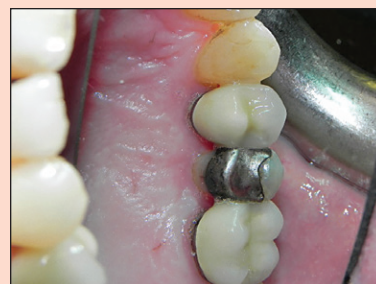**FIGURE 10C**—CL provided and primary closure achieved with 5-0 gut sutures.



**FIGURE 10D**—One-week p/o healing is favourable, but tissues are still fragile and second dressing is placed.

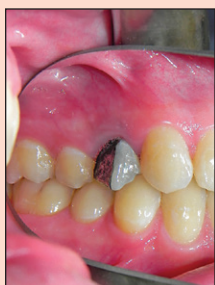

**FIGURE 10E**—Two-week p/o demonstrates more mature tissue healing and third dressing is placed preventing “gingival rebound”. The crown is prepped and impression for crown taken three weeks after surgery. Chlorhexidine staining evident on occlusal surfaces.

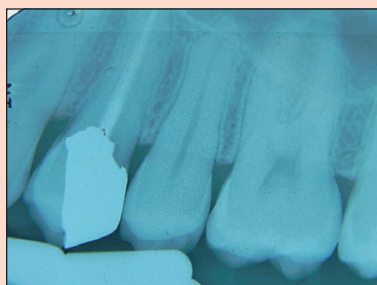


**FIGURE 10F**—14 full coverage restoration in position with minimal loss of interdental papilla (crown restored by Dr. Janice Mummery). CL benefited tooth 25 as well.

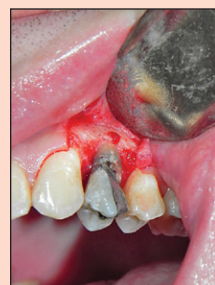**CASE 8.** 23-year-old male with large subgingival amalgam stabilizing an endodontically-treated tooth 24. Full coverage restoration required to stabilize the tooth and prevent crown fracture.



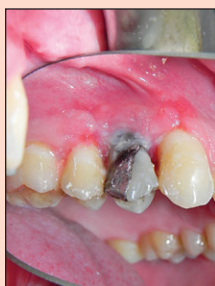**FIGURE 11A**—Pre-operative photo of 24 buccal surface.



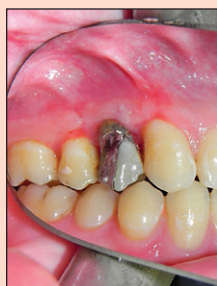**FIGURE 11B**—Radiograph showing dental status.



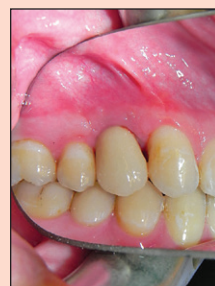**FIGURE 11C**—Surgical procedure provided, exposing deficient margin of amalgam and provided sufficient osteoplasty for the “ferrule effect”.



**FIGURE 11D**—One-week p/o healing after first dressing removed.

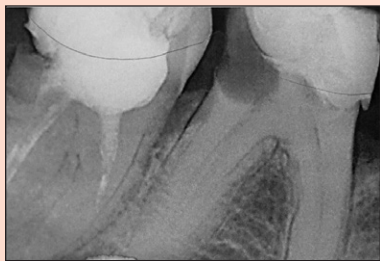


**FIGURE 11E**—Two-week p/o healing after second dressing removed.

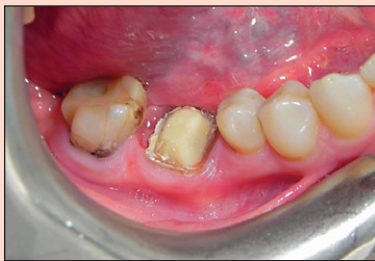

**FIGURE 11F**—Final restoration placed demonstrating gingival harmony (case restored by Dr. Michael Paltsev).

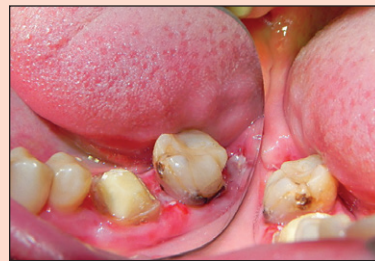**CASE 9.** 41-year-old female with problematic foreign dental treatment. Patient wants to save tooth 46.



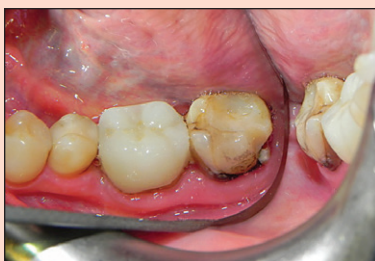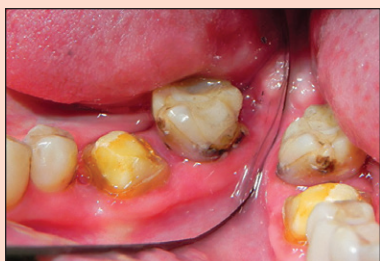**FIGURE 12A**—Pre-treatment radiograph before RCT 46 is provided. Severe tooth decay, periodontal bone loss and overhanging margins are evident.



**FIGURE 12B**—Pre-op view before CL. Temp crown is removed to facilitate surgical access.



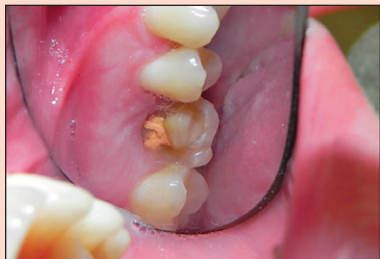**FIGURE 12C**—One-week p/o healing after first dressing removed.



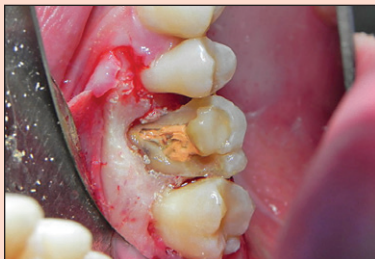**FIGURE 12D**—Two-week p/o after second dressing is removed.

**FIGURE 12E**—E.max ceramic crown completed within one month of CL procedure. Prognosis of tooth 47 is uncertain due to incomplete endodontic therapy in past, but presently asymptomatic (RCT and E.max ceramic crown completed by Dr. Andre Lebed).

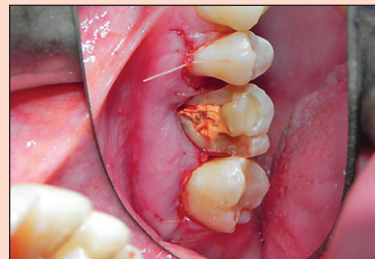**CASE 10.** 17-year-old male had RCT 26 provided at age of 15 without a full coverage restoration. Major buccal tooth fracture occurred. Tooth 26 has “zero” mobility score, and family had aversion for extraction and future implant placement.



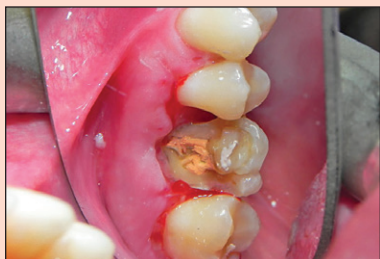**FIGURE 13A**—Pre-treatment photograph of buccal fracture tooth 26.



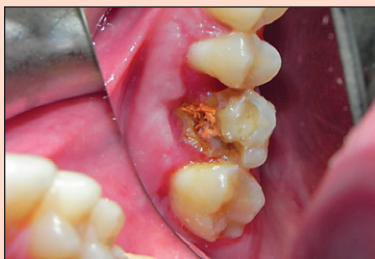**FIGURE 13B**—Surgical exposure of infrabony fracture.



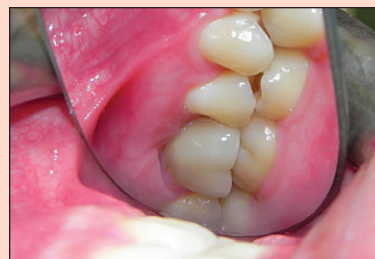**FIGURE 13C**—P/o view after CL following sufficient osteoplasty, and prior to placement of the first periodontal dressing.



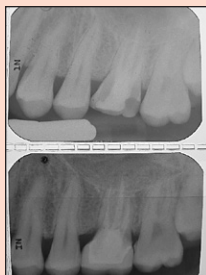**FIGURE 13D**—One-week p/o healing after first dressing is removed.



**FIGURE 13E**—Two-week p/o healing after second dressing is removed.



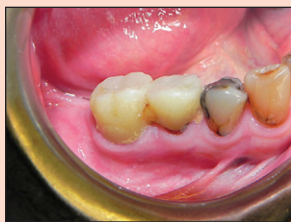**FIGURE 13F**—Restoration completed with reduced buccal contour for stress alleviation (crown completed by Dr. Gordana Lukic).



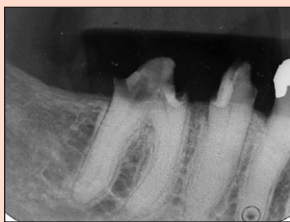**FIGURE 13G**—Pre and post-operative radiographs demonstrating marginal fit of crown 26 (cement on mesial of 27 removed after the radiograph was taken).



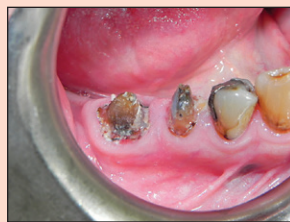**CASE 11.** 96-year-old female with severe tooth decay around teeth 46 and 45 with "zero" tooth mobility score and no endodontic involvement.



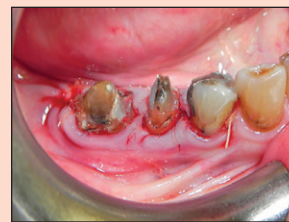**FIGURE 14A**—Photo of temporary splint 46-45 in position.



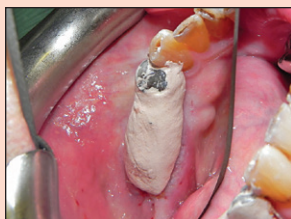**FIGURE 14B**—Pre-operative radiograph after temporary splint 46-45 is removed. Temporary splint allows for removal of decay prior to CL surgery.



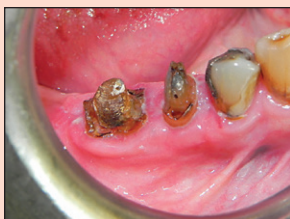**FIGURE 14C**—Pre-operative photo after temporary splint is removed.



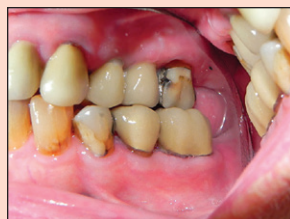**FIGURE 14D**—Block CL provided and primary closure achieved before first dressing is placed.



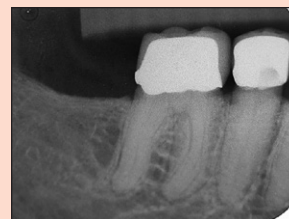**FIGURE 14E**—Periodontal dressing becomes a temporary splint. The dressing also "clamps" and protects the area of surgery.



**FIGURE 14F**—Second week post-op photo after dressing changed twice.

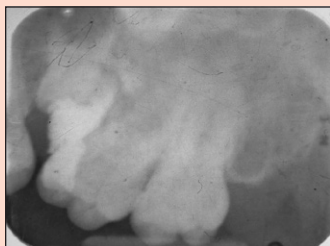

**FIGURE 14G**—Final crowns 46-45 placed with excellent marginal fit.

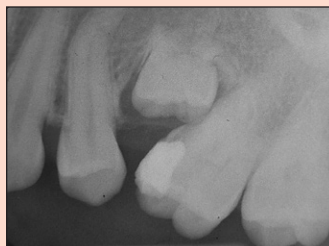

**FIGURE 14H**—Final radiograph demonstrating excellent adaptation of new crowns 45-46 (crowns completed by Drs. John and Joanna Kennedy).

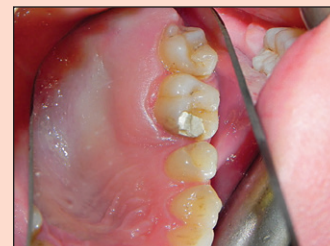**CASE 12.** 29-year-old female with an unusual situation. Retained submerged tooth 65 complicated restorative efforts for tooth decay on the mesial of tooth 26 in a foreign country. Inadvertently, the radiopaque resin material was packed subgingivally, encompassing impacted tooth 65. Canadian dentist identified indication for CL and subsequent placement of suitable restoration. Patient declines removal of 65 at this time, due to potential sinus perforation.



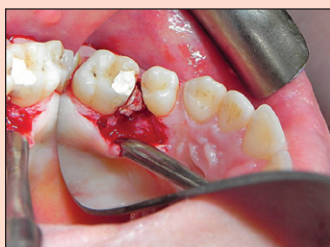**FIGURE 15A**—Radiograph demonstrating excess subgingival cement.



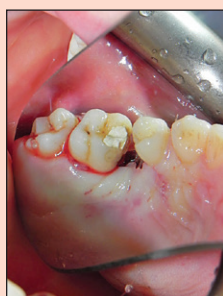**FIGURE 15B**—Radiograph demonstrating removal of excess cement immediately following CL procedure.



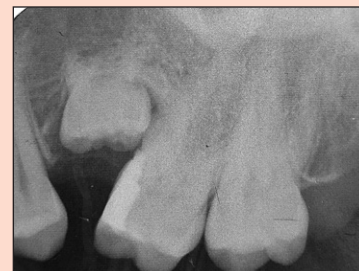**FIGURE 15C**—Pre-operative clinical presentation.



**FIGURE 15D**—Photo demonstrating dental cement exposure.



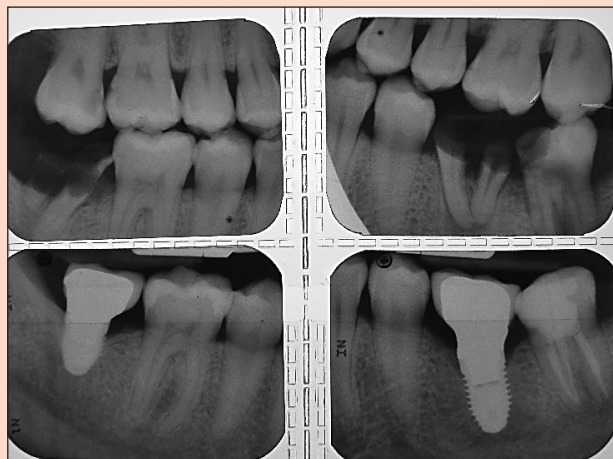**FIGURE 15E**—CL completed. Dressing was changed three times to facilitate final restoration.



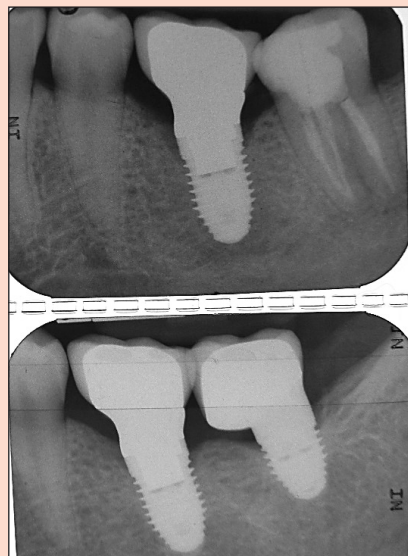
**FIGURE 15F**—Final radiograph demonstrating conservative MO restoration provided three weeks after CL surgery (case restored by Dr. David Sacoransky).



**CASE 13.** 30-year-old lady experienced irregular dental care and presented with multiple areas of dental decay and extensively decayed and fractured roots associated with teeth 47 and 36. This example is more advanced than Figure 3c and teeth 47 and 36 were restored with 6 mm wide implants Nobel Biocare tapered groovy variety, 6 mm x 8 mm area 47 and 6 mm x 10 mm area 36. Post and crown restoration provided by Dr. Roland Schindler.



**FIGURE 16A**—Pre and post-operative radiographs of areas 47, 36 restored with 6 mm wide implants.



**FIGURE 16B**—37 fractured vertically four years following implant placements 36, 47. Radiograph demonstrating 37 transition towards another implant-supported crown.

days after periodontal plasty procedures (gingivectomy), the crevicular epithelium is present in all specimens. This was a histological study on humans (153 patients) and shows how rapidly the gingiva heals with complete epithelialization of the wound in two weeks time after it was completely removed.<sup>12</sup>

There also appears to be a “gingival rebound effect” that occurs following CL procedures that is established up to eight weeks following surgery. Herrero et al<sup>13</sup> compared desired versus actual amount of CL achieved and found that after eight weeks of surgery, the objective of 3 mm between the planned restoration margin and alveolar crest was not routinely achieved. After eight weeks, there appears to be no significant change from baseline parameters including gingival margin position, pocket depth, and the position of the mucogingival junction and alveolar crest.<sup>13</sup> The surgical

technique in this article included gingivectomy and the apical repositioned flap surgery with or without osteoplasty. “Gingival rebound” is associated with thick flat tissue biotype, tooth type and postoperative position of the gingival margin in relation to the osseous crest.<sup>14</sup> Nearly 80 percent of the gingival rebound occurs by

odontal dressing) and maintain that position (while the soft and hard tissues heal), then “capture the margin” after two weeks of healing when complete epithelialization of the wound occurs. A temporary crown restoration could now be considered (for fractured teeth) and if healing is favourable, a permanent restoration

The surgical technique in this article included gingivectomy and the apical repositioned flap surgery with or without osteoplasty

three months following CL.<sup>14</sup> It is worth noting that this may be the first article describing the “gingival rebound effect”.

With so many factors to consider, including gingival rebound, perhaps one’s focus can be to expose the margins of teeth requiring CL conservatively, then hold that position (secured with a peri-

can be pursued depending on the clinical circumstance.

In a recent study, up to 5 mm osteoplasty was required (90 percent of treated cases had more than 3 mm bone removed) to satisfy 3 mm gain of coronal tooth structure (CL) and maintain it up to six month follow-up.<sup>17</sup> Of concern is that 39 percent of adjacent

sites also had significant osteoplasty and there were no recorded measurements of tooth mobility scores pre and post-operatively. A 5 mm of bone adjustment could reflect 30-40 percent of supporting bone for the teeth involved.

Of note is that procedures involving a high degree of osteoplasty have been associated with furcation involvement following the CL procedure.<sup>15</sup> A conservative surgical protocol would therefore favour minimal osteoplasty if possible. In their article, Herrero et al<sup>13</sup> suggested a more aggressive surgical approach during the CL procedure as opposed to “holding the position” of the margin to resolve gingival rebound (periodontal dressing materials can help in this regard).

Furthermore, where there is a chance of violating the BW during tooth preparation after CL, Tseng et al<sup>16</sup> suggested to create an adequate BW by establishing the finished margin of the restoration and fabricating a provisional restoration at the time of surgery. This concept is called “capturing the margin” and favours a more forgiving surgical protocol.

In developing the possibility to “capture the margin” to maintain the benefit of surgical CL without significant osteoplasty, a periodontal surgical dressing can help.<sup>18</sup>

#### VALUE OF A PERIODONTAL PACKING MATERIAL

Periodontal packing materials have been around since 1923 initially developed by A. W. Ward. Several non-eugenol dressings exist and include Coe-Pak (Coe Laboratories), Peri pac (De Trey, Zurich) and Perio Putty.<sup>19,20</sup> Periodontal dressings do not possess significant

anti-bacterial properties<sup>18,21</sup> and may not help with postoperative pain and discomfort,<sup>22</sup> but they do give patients a psychological feel of protection and well-being.<sup>22</sup> Coe-Pak is successful because of its physical properties providing a smoother surface (than other dressings) enhancing the physical barrier to saliva/bacterial contamination and food impaction (“umbrella effect”).<sup>21</sup>

Of great importance is that periodontal dressings improve retention of apically repositioned flaps by preventing coronal displacement<sup>22</sup> providing a “clamp-

### Patients who smoke must be warned that cigarette smoking has a negative impact on periodontal surgery and can delay wound healing

like effect”, and may act as a template for healing by preventing the formation of excess granulation tissue (an additional “clamping effect”).<sup>23</sup> The dressing should be changed on a weekly basis to prevent alteration in the healing pattern due to bacterial growth.<sup>24</sup>

Keeping the above in mind, several case examples are presented here demonstrating the benefits of CL with minimal osteoplasty and close adaptation of soft tissues to help facilitate quicker soft tissue epithelialization and healing. The Coe-Pak periodontal dressing serves as a “clamp” to maintain tissue position and to provide an “umbrella effect”. This will help expose the margin when the dressing is removed and facilitate a “capturing the margin” appointment three weeks later to prevent the “gingival rebound effect”. By that time, significant

periodontal healing has occurred to maximize the ferrule effect and capture 1 mm or more of subgingival tooth structure for retention and resistance form.<sup>5</sup>

#### SUMMARY

Many factors have to be considered to ensure a favourable outcome for the crown lengthening procedure. These include patient co-operation, strategic value of tooth, apical extent of fracture or caries, level of alveolar crest, crown-to-root ratio, level of attached gingiva, and in the anterior region, aesthetic consideration. Patients who smoke must

be warned that cigarette smoking has a negative impact on periodontal surgery and can delay wound healing.<sup>25</sup>

In several clinical situations, crown lengthening can be contraindicated and instead an implant option may have to be considered<sup>26,27</sup> (Fig. 16). Examples include pre-existing tooth mobility, poor crown-to-root ratio and poor post-surgical aesthetics (longer tooth appearance or loss of interdental papilla). Also, CL is contra-indicated if significant osteoplasty is required that can compromise support of adjacent teeth (Fig. 3 – illustration marked c); loss of tooth would be more preferable. Figure 16 (A&B) demonstrates an extreme example of extensive tooth decay, root fracture and endodontic involvement. Four years after teeth 47 and 36 were restored with implants,



tooth 37 developed a vertical root fracture (perio-endo involvement) requiring placement of a third implant. For an example of an anterior implant restoration alternative, please refer to a previous article.<sup>28</sup> Loss of papilla in the anterior region can be devastating and Tarnow et al<sup>29</sup> illustrate this. Under select circumstances, however, a more conservative approach can provide pleasing results (Figs. 4, 5, 6 & 7).

**CONCLUSION**

The modified CL surgical technique described in this article can produce successful clinical results and comes in a timely fashion with very little patient discomfort. The periodontal dressing prevents “gingival rebound” reducing the need for aggressive osteoplasty providing an environment to “capture the margin” for early restorative

*lectured on periodontics and implant dentistry and presently has a private practice restricted to periodontics and implant dentistry in Toronto, Ontario.*

*Eugene Gerald Kryshchalskyj is a third year dental student at the University of Western Ontario in London, Ontario.*

*Alexander Kryshchalskyj is a fourth year student in biological sciences at McMaster University in Hamilton, Ontario.*

*Oral Health welcomes this original article.*

**REFERENCES**

- Ribeiro F.V. et al. Open flap versus flapless esthetic crown lengthening: 12-month clinical outcomes of a randomized controlled clinical trial. J. Periodontol. 2014; 85: 536-544.
- Ong M, Tseng S-C, Wang H-L. Crown lengthening revisited. Clinical Advances in Periodontics. 2011; 1: 233-239.
- Lang NP, Loe H. The relationship between the width of keratinized gingiva and periodontal health. J Periodontol. 1972; 43: 623-627.
- Gargiulo AW, Wentz FM, Orban B. Dimensions and relations of the dentogingival junction in humans. J Periodontol. 1961; 32: 261-267.
- Bragger U, Louchenauer D, Lang NP. Surgical lengthening of the clinical crown. J Clin Periodontol. 1992; 19: 58-63.
- Tarnow D, Stahl SS, Magner A, Zamko KJ. Human gingival attachment response to submerged crown placement – marginal remodelling. J Clin Periodontol. 1986. 13: 563-569.
- Sorensen JA, Engleman MJ. Ferrule design and fracture resistance of endodontically treated teeth. J Prosthet Dent. 1990; 63: 529-536.
- Ahou-Arroj RV et al. Healing time for final restorative therapy following surgical crown lengthenings procedures. A review of related evidence. Clinical

- advances in periodontics. 10. 1902/ cap. 2014. 140014 (in print).
- Deas DE et al. Osseus surgery for crown lengthening: A 6-month clinical study. J Periodontol. 2004; 75: 1288-1294.
- Donnenfeld OW, Hoag PM, Weissman DP. A clinical study on the effects of osteoplasty. J Periodontol. 1970; 41: 131-141.
- Wilderman MN, Pennel BM, King K, Barron JM. Histogenesis of repair following osseus surgery. J Periodontol. 1970; 41: 551-565.
- Stahl SS, Witkin GJ, Heller A, Brown R. Gingival healing III. The effects of periodontal dressings on gingivectomy repair. J Periodontol. 1969; 40: 34-37.
- Herrero F, Scott JB, Maropis PS, Yukna RA. Clinical comparison of desired versus actual amount of surgical crown lengthening. J Periodontol. 1995; 66: 568-571.
- Ritika A et al. Evaluation of supracrestal gingival tissue after surgical crown lengthening: A 6-month clinical study. J Periodontol. 2013; 84: 934-940.
- Dibert et al. Crown lengthening in mandibular molars: A 5-year retrospective radiographic analysis. J Periodontol. 2003; 74: 815-821.
- Tseng et al. Immediate temporization with crown lengthening. Comp Cont Educ Dent. 2011; 32: 38-43.
- Lanning SK et al. Surgical crown lengthening: evaluation of the biological width. J Periodontol. 2003; 74: 468-474.
- Sachs HA et al. Current status of periodontal dressings. J Periodontol. 1984; 55: 689-696.
- Ward AW. Inharmonius cusp relation as a factor in periodontoclasia. J Am Dent Assoc. 1923; 10: 471.
- Ward AW. Postoperative care in the surgical treatment of pyorrhoea. J Am Dent Assoc. 1929; 16: 635.
- O’Neil TCA. Antibacterial properties of periodontal dressings. J Periodontol. 1975; 46: 469-474.
- Checehi L, Trombelli L. Postoperative pain and discomfort with and without periodontal dressing in conjunction with 0.2% chlorhexidine mouthwash after apically positioned flap procedure. J Periodontol. 1993; 64: 1238-1242.
- Lindhe J. Textbook of Clinical Periodontology. p 388. Copenhagen-Munksgaard International Publishers, Ltd. 1983.
- Heaney TG, Appleton J. The effect of periodontal dressing on the healthy periodontium. J Clin Periodontol. 1976; 3: 66.
- Preber H, Berstrom J. Effect of cigarette smoking on periodontal healing. J Clin Periodontol. 1990; 17: 324-328.
- Lundgren D, Rylander H, Laurell L. To save or to extract, that is the question. Natural teeth or dental implants in periodontitis-susceptible patients: Clinical decision making and treatment strategies exemplified with patient case presentations. Periodontology 2000. 2008; 47: 27-50.
- Avila G et al. A novel decision making process for tooth retention or extraction. J Periodontol. 2009; 80: 476-491.
- Kryshchalskyj E, Kryshchalskyj EG, Kryshchalskyj AM. Clinical application of the mucogingival subepithelial connective tissue graft. Oral Health. 2013; Oct: 18-30.
- Tarnow D et al. Vertical distance from the crest of bone to the height of the interproximal papilla between adjacent implants. J Periodontol. 2003; 74: 1785-1788.

**The modified CL surgical technique described in this article can produce successful clinical results and comes in a timely fashion with very little patient discomfort**

endeavours. An informed patient and case selection are pivotal in the treatment planning process. **OH**

*Dr. Eugene Kryshchalskyj was an associate clinical instructor at the University of Toronto Faculty of Dentistry’s Periodontics Division for over 10 years and published many articles on periodontics in referenced journals. He has also*



Reprinted with permission from Oral Health Group Magazine - A Newcom Media Inc Publication